

# Septic arthritis caused by *Salmonella* sp.

W Hambali,<sup>1</sup> Sumariyono,<sup>2</sup> K Chen<sup>3</sup>

<sup>1</sup> Department of Internal Medicine, Faculty of Medicine University of Indonesia; <sup>2</sup> Rheumatology Division, Department of Internal Medicine, Faculty of Medicine University of Indonesia; <sup>3</sup> Infection and Tropical Medicine Division, Department of Internal Medicine, Faculty of Medicine University of Indonesia.

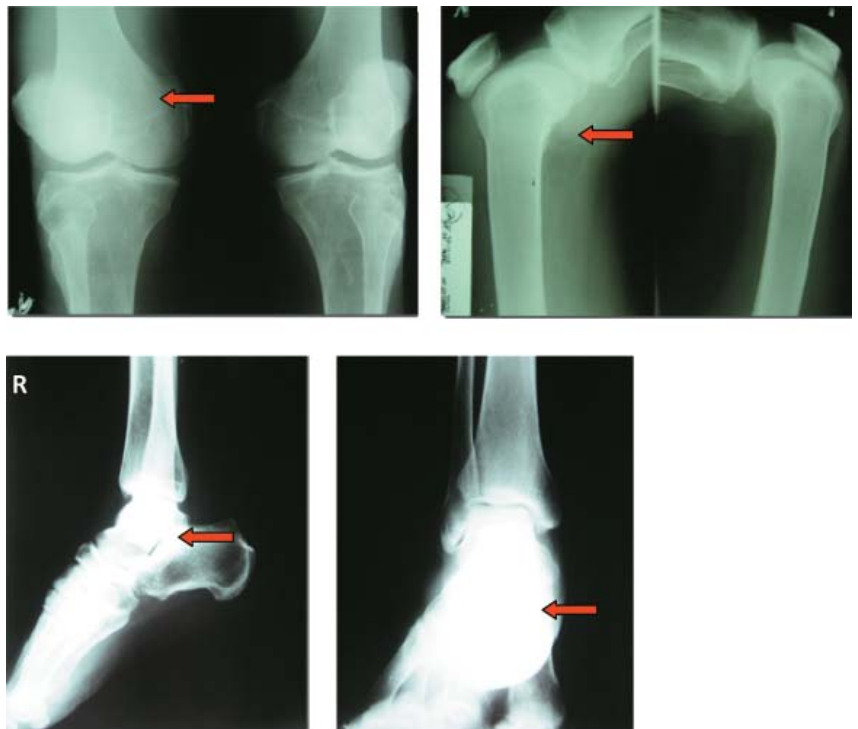Septic arthritis is a rare joint disorder, and can be caused by various pathogenic microorganisms, including bacteria, virus, mycobacterium, and fungus. The incidence of this infection is between 2 to 10 cases per 100,000 populations annually and can reach as high as 30 to 70 cases per 100,000 in immunodeficient population. This disorder is frequently unidentified in early phase of the disease due to its unspecific symptoms and signs.<sup>1</sup> This joint infection can cause numerous problems to the patient ranging from joint damage, bone erosion, osteomyelitis, fibrosis, ankylosis, sepsis, or even death.<sup>1-5</sup> The case-fatality rate for this disorder can reach up to 11%, comparable to the case fatality rate for other community infections such as pneumonia.<sup>2,6</sup>

*Salmonella* sp. is a Gram-negative bacillus bacterium with main invasion predilection in intestinal villi.<sup>7</sup> This microorganism rarely causes septic arthritis although several cases have been reported before. Ortiz-Neu et al. demonstrated that septic arthritis caused by *Salmonella* sp. has high relapse incidence and a tendency to turn chronic, making the treatment more difficult and challenging.<sup>8</sup>

## CASE ILLUSTRATION

A 65 year old male came to emergency room with chief complain of having unilateral knee and ankle joint swelling since 2 days prior to admission. There was continuous pain sensation, fever, and reduced range of movement sensed by the patient. The joints were reddish on inspection and warm on palpation. There was history of nephrotic syndrome documented 2 months before, which was treated with prednisone 15 mg t.i.d. and simvastatin 10 mg q.d. There was no history of local trauma and diabetes mellitus. History of typhoid fever was denied. Laboratory examination revealed marked leucocytosis (15,300/uL), hyponatremia (129 mmol/L), hypoalbuminemia (1.5 mg/dL), while urine analysis showed proteinuria (2+), erythrocyte of 10-15/High Power Field, and no active cast were seen on microscopic examination. Random Blood Glucose was 116 mg/dL, BUN and blood creatinine level were 45 mg/dL and 0.7 mg/dL respectively. Other clinical and laboratory findings were unremarkable. Joint plain radiography showed tissue swelling and no other abnormalities were noted. There was no erosion and osteophyte, whereas narrow space and alignment were within normal limit.

Figure 1  
Roentgenographic appearance of right knee and ankle joint, showed unspecific tissue swelling. There was no other abnormalities were noted.



Septic arthritis was suspected and prompt empirical antibiotic treatment using combination of ceftriaxone 2 gr q.d. and ciprofloxacin 500 mg b.i.d. were given. Paracetamol 500 mg q.i.d. was started and the joints were fixated on anatomical position. Joint puncture on knee joint were done on the first day of hospitalization, aspirated 25 cc whitish purulent fluid that indicated active joint infection. On the third day of hospitalization, joint fluid analysis result showed leucocyte level of 68,000/uL, translucent turbidity, low viscosity, poor mucinous test, negative crystal precipitate, and negative fast acid staining. Blood uric acid level was 3.7 mg/dL and leucocyte level was 19,200/uL. Analgetic drug was escalated using tramadol 50 mg t.i.d., and knee joint puncture was performed again, aspirated 45 cc whitish purulent fluid. Antibiotic regimen was still given with the same combination.

On the eighth day of hospitalization, fluid culture showed growth of *Salmonella sp.*, which was sensitive to ampicillin, coamoxiclave, amikacin, gentamicin, tetracycline, cotrimoxazole, ciprofloxacin, levofloxacin, cefazolin, cefuroxime, ceftazidime, cefotaxime, ceftriaxone, cefoperazone, imipenem, and meropenem, besides resistance to chloramphenicol. The highest sensitivity was shown by ceftriaxone, with sensitivity zone of 33 mm. Blood sample analysis for PCR test against *Salmonella* and Tubex Test (IgM anti *Salmonella*) was negative and weak positive respectively. Laboratory result for hsCRP was 108.0 mg/L (N < 10.0 mg/L) indicating active inflammation. Based on these results ceftriaxone dosage was escalated to 3 gram q.d. and ciprofloxacin injection was stopped.

On the twelfth day of hospitalization patient showed considerable clinical improvement and radiographic examination showed neither cartilage destruction nor osteomyelitis. Joint range of movement was good and leucocyte level decreased to 11,200/uL. The antibiotic was continued until the third week, and the patient was discharged using cefixime 100 mg b.i.d. and meloxicam 7.5 mg on p.r.n. basis for another 2 weeks. The result of the treatment was good.

## DISCUSSION

Acute oligoarthritis accompanied with sensation of pain, fever, as well as reduced range of movement were the first symptoms complained by the patient. Infection of the joint space should always be suspected in this condition, and prompt empirical antibiotic treatment is justifiable without documented joint fluid analysis and culture results. Joint aspiration to relieve the patient's symptoms and to obtain joint fluid for analysis should be performed immediately. Any delay in carrying out these points can amplify the patient's mortality and morbidity, increasing the risk of joint damage, bone erosion, osteomyelitis, fibrosis, ankylosis, and sepsis.<sup>1-4</sup>

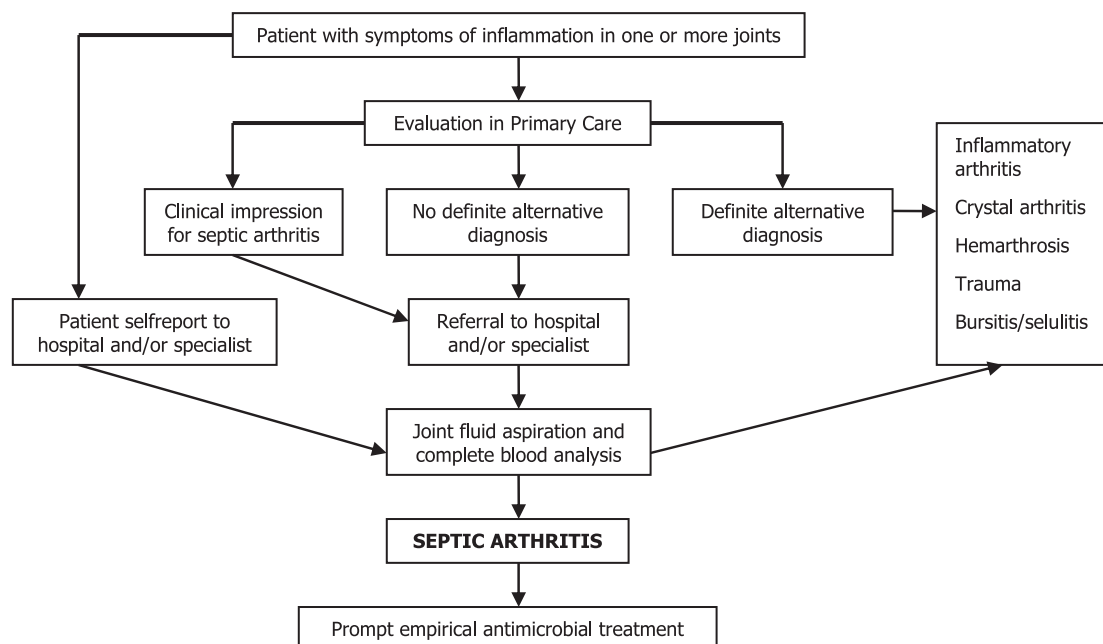
Several conditions are correlated to the increment risk for septic arthritis such as degenerative joint disease, rheumatoid arthritis, diabetes mellitus, leukemia, corticosteroid usage, hepatic cirrhosis, granulomatous disease, malignancy, immunodeficient state, older age, kidney disease, and hypogammaglobulinemia.<sup>4,5</sup> *Salmonella*-related septic arthritis that was identified in the patient had apparently similar risk factor including older age, use of high dose glucocorticoid, and kidney disease. The symptoms of acute arthritis in knee and ankle joint that had developed in this patient were also comparable to conventional predilection joint for non gonococcal septic arthritis counting knee for 40-50%, hip for 20-25%, and shoulder, wrist, ankle for 10-15% respectively.<sup>1,4,9</sup>

*Salmonella sp.* is rarely reported as the causative microorganism for septic arthritis, although several cases have been reported before.<sup>8</sup> Classic symptoms of joint infection that consist of acute joint swelling and inflammation accompanied with progressive pain and fever are also observed in this *Salmonella*-related septic arthritis. Immediate joint aspiration can relieve acute symptoms of inflammation in this case and proven beneficial in identifying the causative microorganism. The analysis for joint fluid caused by *Salmonella*-related septic arthritis is similar to the results of joint infection caused by another classic microorganisms, that include whitish appearance, low viscosity, poor mucinous test, high level of leucocytes, and translucent turbidity. Leucocytosis and elevation of acute phase reactant (hsCRP) were also observed in this case.

The infection was thought to had originate from systemic transmission that underwent bacteremia and then spread to the joint, although the patient denied any history of typhoid fever before. Negative result for PCR test against *Salmonella sp.* and weak positive for Tubex Test showed previous infection of this microorganism that was presumed subclinical. This finding is parallel to general acceptance, in which majority of joint infection is caused by focal infection in another organ that has spread to the joint space through vascular bed in synovium membrane.<sup>1,9</sup> Lack of limiting basement membrane in the synovium tissue reduces the ability of the joint to prevent infection spreading.

Recommendation for using broad spectrum of empirical antibiotic treatment, such as third generation cephalosporin, seems reasonable in this case. Prolonged use of intravenous antibiotic followed by oral antibiotic is needed in this case before clinical improvement is seen. This fact is parallel to the study conducted by Gupta et al, in which intravenous and oral antibiotic are given for median 15 days and 21 days respectively before improvement is observed.<sup>2</sup>

Figure 2 Algorithm for the treatment of patients with suspected joint infection (adapted from Coakley et al., 2006)<sup>6</sup>



## CONCLUSION

Septic arthritis is a rare condition and frequently unidentified in the early phase of the disease, due to its unspecific symptoms and signs. This disorder can lead to a number of complaints from the patient, and can cause significant increment in morbidity and mortality rate. *Salmonella sp.*, a Gram-negative bacillus bacterium with its main predilection in the human intestine can cause septic arthritis through systemic bacteremia. Risk factors, clinical symptoms, and laboratory examination in *Salmonella*-related septic arthritis are similar to the findings of septic arthritis caused by other traditional microorganisms.

According to the current recommendation, joint aspiration is mandatory, proven beneficial in relieving symptoms, and used to identify the underlying microorganisms. The resistance patterns that are obtained from microorganism culture could accommodate the use of the appropriate antibiotic. Prompt empirical antimicrobial therapy with broad spectrum antibiotics that are used in most cases is acceptable in this case.

## REFERENCES

1. Madoff LC, Thaler SJ, Maguire JH. Infectious arthritis. In: Kasper DL, Braunwald E, Fauci AS, Hauser SL, Longo DL, Jameson JL, editors. *Harrison's principle of internal medicine*. 16<sup>th</sup> edition. New York: McGraw Hill; 2005. p. 2050-5.
2. Gupta MN, Sturrock RD, Field M. A prospective 2-year study of 75 patients with adult-onset septic arthritis. *Rheumatology* 2001;40:24-30.
3. Ryan MJ, Kavanagh R, Wall PG, Hazleman BL. Bacterial joint infection in England and Wales: analysis of bacterial isolates over a four year period. *Brit J Rheumatology* 1997;36:370-3.
4. Ho G, Jue SJ, Cook PP. Arthritis caused by bacteria or their component. In: Harris ED, Budd RC, Firestein GS, Genovese MC, Sargent JS, Ruddy R, editors. *Kelley's textbook of rheumatology*. 7th edition. Philadelphia: Elsevier Saunders; 2005.
5. Ho G. Septic arthritis. In: Stone JH, Crofford LJ, White PH, editors. *Primer on the rheumatic disease*. New York: Springer Science; 2008. p. 271-6.
6. Coakley G, Mathews C, Field M, Jones A, Kingsley G, Walker D. BSR&BHPR, BOA, RCGP and BSAC guidelines for management of the hot swollen joint in adults. *Rheumatology* 2006;45:1039-41.
7. Karsinah, Lucky HM, Suharto, Mardiasuti HW. Gram negative rod: *Salmonella*. [Batang Gram negative: *Salmonella*] In: Syahrurachman A, Chatim A, Soebandrio A, Karuniawati, Santoso AUS, Harun BMH, editors. *Text book of medical microbiology*. [Buku ajar mikrobiologi ke-dokteran] Jakarta: Binarupa Aksara; 1993. p. 168-73.
8. Govender S, Chotai PR. *Salmonella* osteitis and septic arthritits. *J Bone Joint Surgery [Br]* 1990;72-B:504-6.
9. Shirtliff ME, Mader JT. Acute septic arthritis. *Clin Microbiol Rev* 2002;15:527-44.